



## PATIENT

Melo Hammond

## SPECIES

Feline

## BREED

DSH

## SEX

Male Neutered

## AGE

4 years

## WEIGHT

4.81kgs

## INTERPRETED BY

Maggie Machen Lamy,  
DVM, DACVIM  
(Cardiology)

## IMAGING PERFORMED BY

Nigel Gumley, DVM

## HOSPITAL NAME

Cedarview Animal  
Hospital

## REFERRING VET

Dr. Bell

## INVOICE

26145

## DATE

9/1/22

## PRESENTING CLINICAL SIGNS

History: Grade 2/6 heart murmur auscultated by rDVM on routine exam. No clinical issues currently. No murmur auscultated today. ECG suggested R axis shift. Sedated with Butorphanol 0.2mg/kg and ketamine 2mg/kg IV.

## ECHOCARDIOGRAM FINDINGS

2D, m-mode, color flow and doppler imaging is available. The left ventricular wall is normal in dimension. There is a mildly hyperechoic endocardium consistent with mild fibrosis. The papillary muscles are normal in size and hyperechoic. The endocardium appears normal. The left atrium is normal in size. The right atrium is normal in size. The right ventricle appears normal. The mitral valve is normal in structure and mobility. Normal flow through both the RVOT and LVOT. No TR. No AI or PI. No pleural or pericardial effusion seen. No obvious cardiac tumors.

## CARDIAC CHART

| FELINE CARDIAC PARAMETERS  | BODY WEIGHT (kg)               | HR (BPM)  | IVSd (cm)<br><small>(Moise, Pipers)</small>                | LVIDd (cm)<br><small>(Moise, Pipers)</small> | LWVd (cm)<br><small>(Moise, Pipers)</small> | FS (%)                           | EF (%)                        |
|--|--------------------------------|---|--|--|---|----------------------------------|-------------------------------|
| NORMAL PARAMETER   | -----                          | 150-240   | 0.35-0.55  | <2<br>(mean 1.5)                             | 3.5-0.55                                    | 35-67                            | 80-100                        |
| PATIENT  | 4.81                           | 164   | 0.45   | 1.48   | 0.50  | 52                               | 86                            |
| FELINE CARDIAC PARAMETERS  | LA/AO<br><small>(Boon)</small> | LA/AO HEART BASE (Swe)<br><small>(Abbott)</small> | LA 2D short axis Base view (cm)<br><small>(Abbott)</small> |  | LVOT VEL<br><small>(m/s)</small>            | RVOT VEL<br><small>(m/s)</small> | E max<br><small>(m/s)</small> |
| NORMAL   | <1.5                           | <1.3  | <1.2   |  | <1.6  | <1.3                             | <0.9                          |
| PATIENT  | 1.2                            | 1.2   | 1.1  |  | 0.75  | 0.8                              | NM                            |
| <p><i>*Note: All measurements based upon multi-modal images and methods. An average value is reported.</i><br/>Adapted from June Boon, Veterinary Echocardiography, 1998<br/>Abbott J &amp; MacLean H JVIM 2006;20: 111-119, Moise et al. Am J Vet Res 47:1476, 1986. Pipers et al. Am J Vet Res 40:882, 1979.</p> |                                |   |  |  |   |                                  |                               |

## INTERPRETATION OF THE FINDINGS & FURTHER RECOMMENDATIONS

Overtly normal cardiac structure and function. The LV wall thickness is normal and there is no evidence of elevated left atrial pressure. No obvious congenital issues are documented. No cause for the murmur is identified in this study, making it likely physiologic in origin. Should the murmur persist or progress significantly, reassessment is certainly advised.

Given these findings, no medications are indicated. It is important to note that phenotypic HCM can develop at any phase of life in cats and often does not accompany a heart murmur or PE abnormalities. Periodic screening is ideally recommended in all cats.

No cardiac contraindication for general anesthesia at this time.

Recommend recheck echocardiogram in 1 year to screen for any progressive changes.



**PATIENT**

Melo Hammond

**SPECIES**

Feline

**BREED**

DSH

**SEX**

Male Neutered

**AGE**

4 years

**WEIGHT**

4.81kgs

**INTERPRETED BY**

Maggie Machen Lamy,  
DVM, DACVIM  
(Cardiology)

**IMAGING  
PERFORMED BY**

Nigel Gumley, DVM

**HOSPITAL NAME**

Cedarview Animal  
Hospital

**REFERRING VET**

Dr. Bell

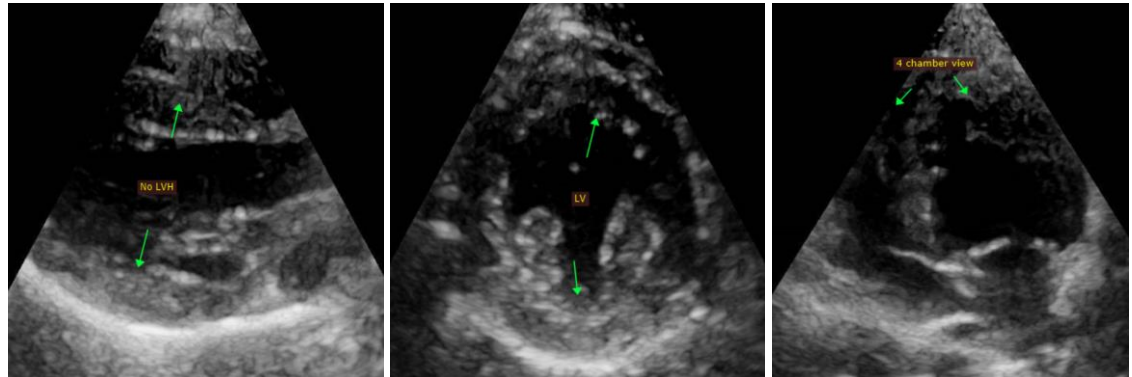
**INVOICE**

26145

**DATE**

9/1/22

**IMAGES**



The information and recommendations provided are based on the images presented by the referring veterinarian. No evaluation can be communicated regarding pathology that was not visible in the image/video clips provided.

Thank you for this referral. This report was generated using transcription software, and minor dictation errors may be present. If the clinical or image interpretation does not parallel your findings or if I can be of any further assistance, please contact me.

Maggie Machen Lamy, DVM  
Diplomate of the American College of Veterinary Internal Medicine (Cardiology)  
info@sonopath.com